

Abstract: FR-PO628

ESRD Secondary to Oxalate Nephropathy Post Whipple's Procedure: A Report of an Interesting Case

Session Information

- Trainee Case Reports - IV October 26, 2018
- Location: Exhibit Hall, San Diego Convention Center
- Abstract Time: 10:00 AM - 10:00 AM

Category: Trainee Case Reports

- 402 Bone and Mineral Metabolism: Clinical

Authors

- Arif, Azka, Kansas City University of Biomedical Sciences Graduate Education Program, Joplin, Missouri, United States
- Hassan, Ahmad, Rawalpindi Medical College, Rawalpindi, Pakistan
- Syed, Leena, Quaid-e-Azam Medical College, Bahawalpur, Pakistan
- Niazi, Muhammad Moosa, Rawalpindi Medical College, Rawalpindi, Pakistan
- Khan, Talal Ali, Freeman Health System, Joplin, Missouri, United States

Introduction

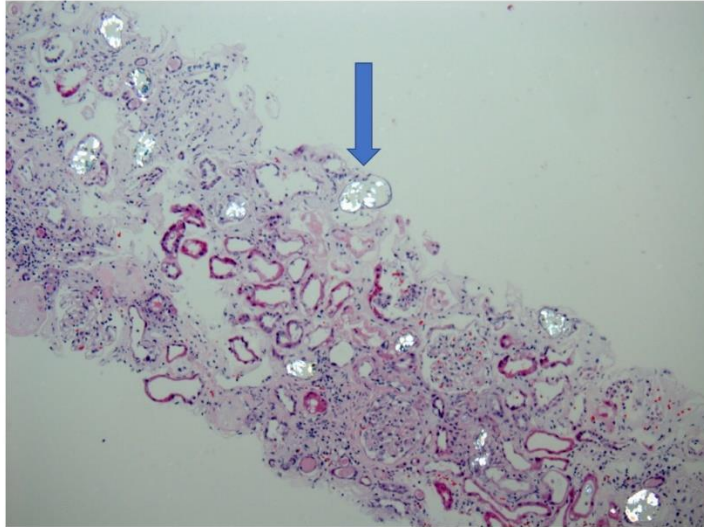
HTN & DM are the two most common causes of ESRD. Secondary Oxalate Nephropathy is one of the rare causes of ESRD, We present an interesting case of ESRD secondary to oxalate nephropathy resulting from Pancreatic Exocrine deficiency.

Case Description

77-year-old male with recently diagnosed HTN ,presented to ER with generalized weakness, nausea, vomiting & swelling. Initial labs showed BUN of 109mg/dl, creatinine of 14.8 mg/dL. No recent IV contrast exposure,no NSAIDs use, no evidence of hematuria, had 0.5 g of proteinuria & negative urine eosinophils. Immune workup was negative.Renal ultrasound was negative for hydronephrosis.He was urgently dialyzed & later on underwent kidney biopsy which showed evidence of oxalate nephropathy & significantly advanced fibrosis. Patient had history of Whipple's procedure in 1996 , he was not on any pancreatic enzyme supplementation .He had history of chronic recurrent diarrhea.His serum lipase was <10 U/L & serum Albumin was 2.8mg/dl.He was deemed ESRD & continued hemodialysis.He was started on pancreatic enzymes and his diarrhea improved.

Discussion

Our case represents one of the rare complications of pancreatic exocrine insufficiency resulting from Whipple's procedure.Pancreatic insufficiency is associated with fat malabsorption causing calcium chelation. Resulting Hyperoxaluria causes oxalate nephropathy. Our case presents a rare yet unfortunate long-term complication of pancreatic insufficiency post Whipple's procedure. Patients especially after Gut related surgeries should be monitored for any hyperoxaluria which can result in lifelong morbidity.



Oxalate Crystals Under Polarized Light in Renal Biopsy specimen